

Iris Flocculi in a 28 Year-Old Woman

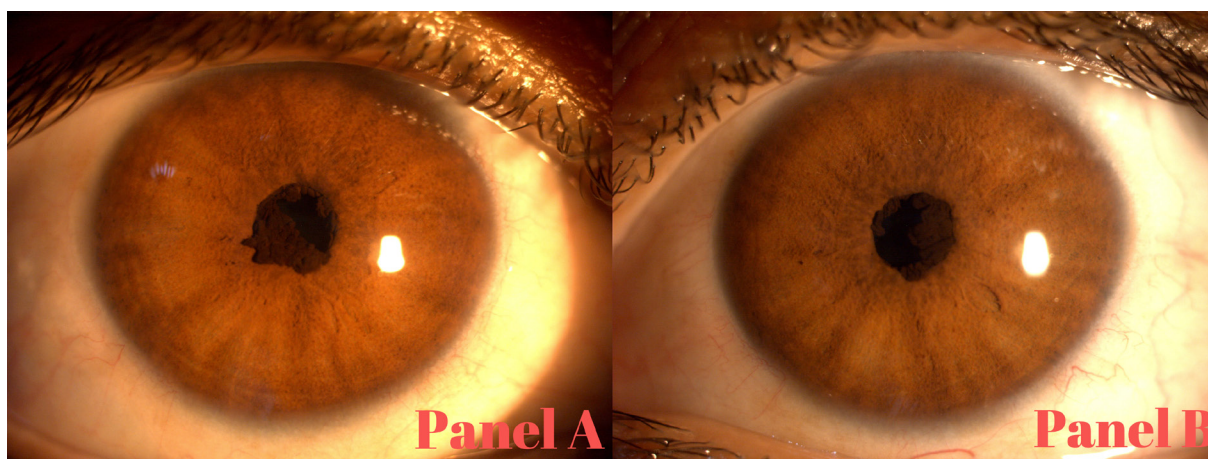
Ali Mahdavi Fard, Leili Pourafkari, Nader D. Nader

Department of Anesthesiology, University at Buffalo, Buffalo, New York, USA

Correspondence: *leili.p@gmail.com*; Tel.: + 1 716 345 79 09; Fax.: + 1 716 862 62 73

Received: 30 July 2021; **Accepted:** 21 October 2021

Key Words: Iris Flocculi ■ Aortic Aneurysm ■ Visual Acuity.



A 28-year-old asymptomatic woman presented to the Eye clinic for routine examination. Slit-lamp examination showed the presence of multiple wrinkled dark-brown excrescences of the iris along the pupillary border in both eyes compatible with a diagnosis of iris flocculi (Panel A and Panel B). The patient stated she had the lesions for a long time. Visual acuity and intraocular pressure were normal. Iris flocculi are pigmented epithelial cysts along the pupillary margin that can wax and wane overtime. They typically are asymptomatic and do not result in any visual symptoms and are considered as isolated and benign, requiring no treatment. Laser photocoagulation with cyst rupture or

surgical excision of the cysts may be considered in symptomatic cases. The condition is important for the occasional association with aortic aneurysms and dissection due to a shared mutation of smooth muscle gene alpha-actin 2 (ACTA-2) and myosin heavy chain (MYH-11). In such cases, congenital mydriatic pupil with loss of accommodation secondary to smooth muscle dysfunction could also occur. It is recommended to screen all affected patients and family members for aortic aneurysm. The patient underwent chest CT which did not show aortic aneurysm.

Conflict of Interest: The authors declare that they have no conflict of interest.