

A Rare Cadaveric Case Report of the Median Nerve Passing Through the Brachialis Muscle

Georgios Paraskevas¹, Christos Lyrtzis¹, Georgios Trikoilis¹, Alexia Maistrellis¹, Maria Piagkou²

¹Department of Anatomy and Surgical Anatomy, Medical School, Aristotle University of Thessaloniki, Thessaloniki, Greece,

²Department of Anatomy, School of Medicine, National and Kapodistrian University of Athens, Athens, Greece

Correspondence: lyrtzischristos@gmail.com; Tel.: + 30 697 7200064

Received: 9 January 2026; **Accepted:** 4 March 2026

Abstract

Objective. To describe a rare cadaveric topographical variation of the median nerve (MN) involving an atypical relationship with the brachialis muscle (BM). Such variations, although uncommon, may complicate surgical procedures, regional anesthesia, and imaging interpretation. This report documents a variation in which the MN traverses the BM without providing motor innervation. **Case Report.** During the routine dissection of the right upper limb of a 75-year-old male donated cadaver, a unilateral (right-sided) topographical variation of the MN was identified. The MN diverged from its usual close association with the brachial artery (BA) and followed a medial and posterior course toward the BM. Within the middle third of the arm, the nerve penetrated a macroscopically distinct bundle of BM fibers, traversed the muscle belly, and exited in its distal third. Distally, the MN resumed a superficial course, re-approached the BA, and continued normally through the cubital fossa. No motor or accessory branches from the MN to the BM were identified during its intramuscular course. The surrounding muscle fibers closely encircled the nerve along its intramuscular segment, indicating a restricted anatomical corridor. The musculocutaneous nerve, BA, and the remaining neurovascular structures followed their typical anatomical pathways. **Conclusion.** This anatomical configuration may represent a potential anatomical substrate for proximal MN irritation or compression and may clinically resemble pronator teres syndrome. Awareness of such variants is important for clinicians evaluating MN neuropathies and for surgeons, anesthesiologists, and radiologists working in the anterior compartment of the arm.

Key Words: Median Nerve ▪ Brachialis Muscle ▪ Entrapment Neuropathy ▪ Anatomical Variation.

Introduction

The median nerve (MN) is a terminal branch of the brachial plexus formed by contributions from the lateral and medial cords. In the arm, it typically descends in close association with the brachial artery (BA), initially lying lateral to the artery before crossing anteriorly to reach its medial side. In the distal arm, the MN lies superficial and medial to the brachialis muscle (BM), which does not normally innervate.

Although uncommon, several topographical and morphological variations involving the relationship between the MN and BM have been

reported. These include the presence of an accessory MN branch supplying the BM (1), variants in which both the MN and BA traverse the BM (2), and passage of the MN through a musculo-fascial tunnel formed by the BM and the medial intermuscular septum, frequently associated with muscular innervation (3). Penetration of the BM by the MN following separation from the BA has been described only rarely in the literature (4). Recognition of such variants is clinically important, as deviations from the typical MN course may predispose the nerve to irritation or compression and complicate surgical approaches, regional anesthesia, and radiological interpretation.

In this report, we describe a rare cadaveric case in which the MN traversed the BM without providing motor innervation.

Case Report

During the routine dissection of the right upper limb of a 75-year-old formalin-fixed Greek male cadaver donated to the Department of Anatomy and Surgical Anatomy at the Medical School, Aristotle University of Thessaloniki, an unusual unilateral course of the MN was observed. The cadaver had been donated pre-mortem with written informed consent, and the study complied with institutional ethical standards for anatomical donation. The anomaly was evident at the level where the short and long heads of the biceps brachii (BB) muscle fused. At this point, the MN, comprised of two lateral roots and one medial root, diverged from its typical close association with the BA (Figure 1), coursing medially and posteriorly toward the BM (Figure 2).

At the level of the origin of the BM to the proximal portion of the distal third of the humerus, the

MN coursed deeper toward the brachialis fascia. Within the middle third of the BM, a macroscopically distinct bundle of muscle fibers projected anteriorly and was penetrated by the MN. The MN traversed the muscle belly and exited at the distal third of the humerus. Beyond this point, the MN resumed a more superficial course, reapproached the BA, and continued its typical anatomical pathway through the cubital fossa, near the midpoint of the pronator teres muscle. The morphological features of this variation are illustrated in Figure 3.

Further meticulous macroscopic dissection confirmed that no motor or accessory branches arising from the MN supplied the BM during its intramuscular course. The surrounding muscle fibers closely encircled the nerve along its intramuscular segment, indicating a restricted anatomical corridor. Because cadaveric findings cannot replicate *in vivo* biomechanical conditions, no definitive conclusion regarding functional nerve compression can be drawn; however, this configuration may represent a potential anatomical substrate for MN irritation under physiological

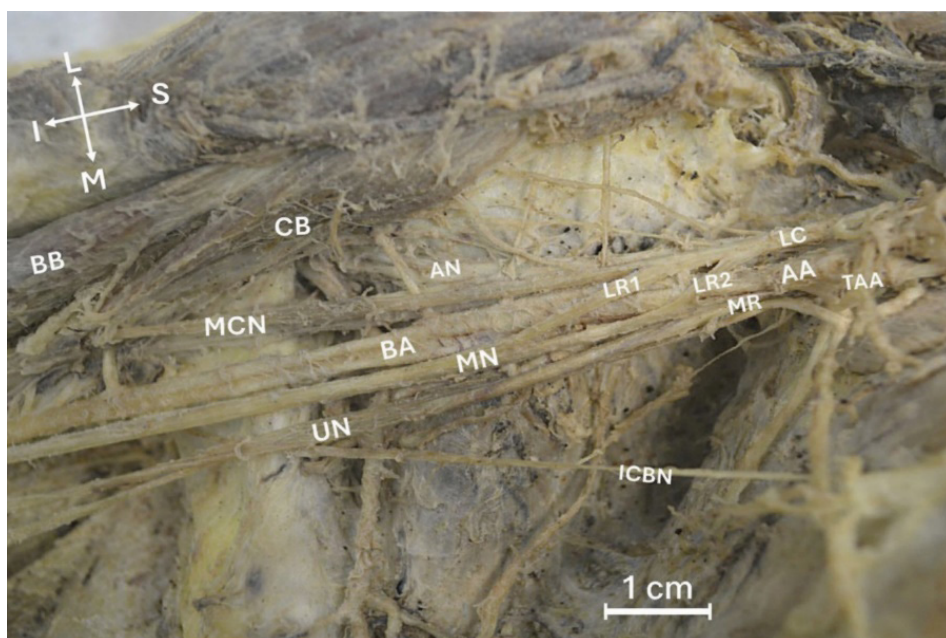


Figure 1. Anterior view of the proximal right upper limb demonstrating the formation of the median nerve (MN) by the union of its two lateral roots (LR1, LR2) and medial root (MR). The MN is shown immediately distal to its formation, in close proximity to the brachial artery (BA). The lateral cord (LC) of the brachial plexus gives rise to the lateral roots, while the axillary artery (AA) and thoracoacromial artery (TAA) are identified in the proximal region. The musculocutaneous nerve (MCN), ulnar nerve (UN), intercostobrachial nerve (ICBN), biceps brachii (BB), coracobrachialis (CB), and the axillary nerve (AN) are also labeled. Orientation markers indicate superior (S), inferior (I), medial (M), and lateral (L). Scale bar = 1 cm.

conditions. The site of nerve penetration and its intramuscular course are illustrated in Figure 3. This topographical variation was unilateral, while

the musculocutaneous nerve, BA, and remaining neurovascular structures of the anterior arm compartment followed their typical courses.

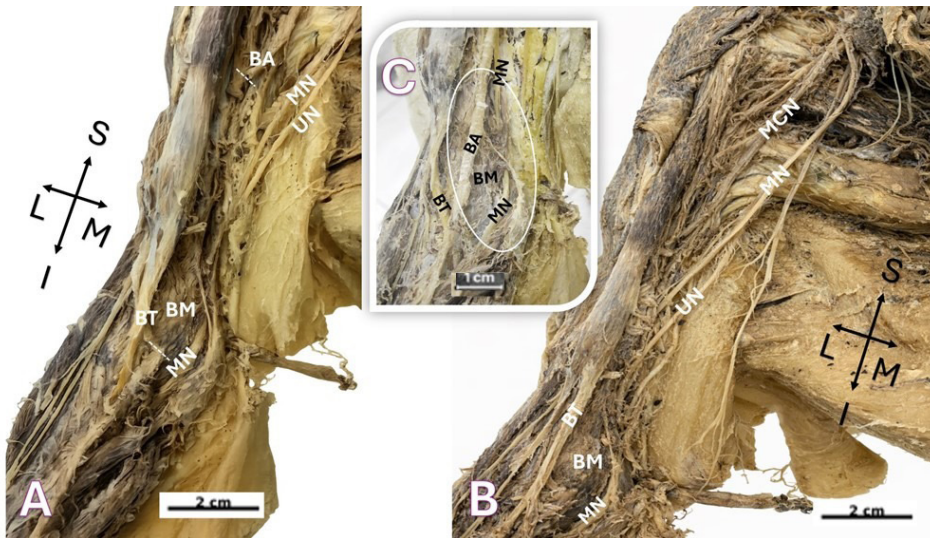


Figure 2. Panoramic anteromedial views of the right upper limb demonstrate an atypical intramuscular course of the median nerve (MN). (A) Proximal view showing the MN and ulnar nerve (UN) descending along the arm toward the brachialis muscle (BM). The brachial artery (BA) is transected (dotted line), and the bicipital tendon (BT) is identified for anatomical orientation. (B) Intermediate view illustrating the MN penetrating and traversing the middle third of the BM. The musculocutaneous nerve (MCN), UN, BT, and BM are labeled for reference. (C) Magnified view highlighting the point at which the MN enters and courses within the substance of the BM. BA and BM are shown in close relation to the intramuscular segment of the MN. Orientation markers denote superior (S), inferior (I), medial (M), and lateral (L). Scale bars=1 and 2 cm.

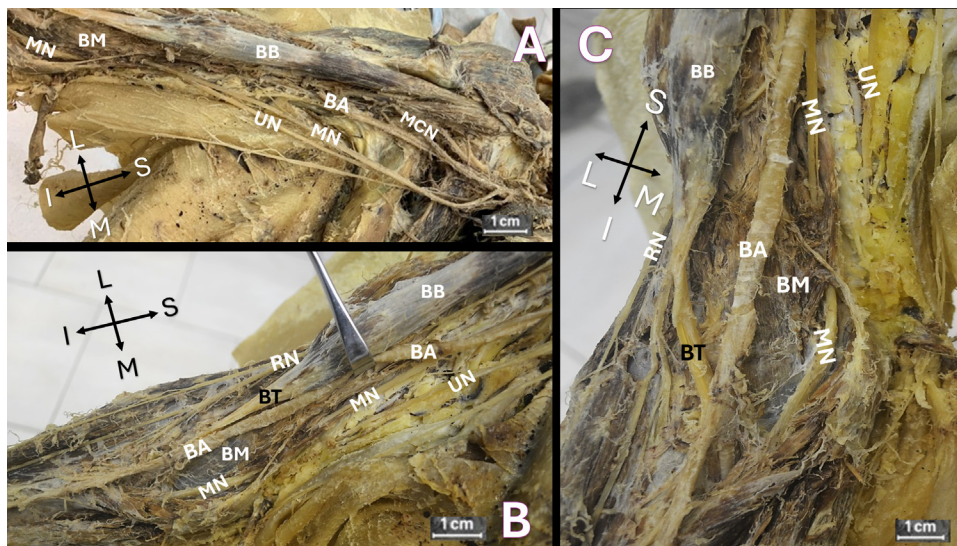


Figure 3. Composite views demonstrate the intramuscular segment of the median nerve (MN) within the brachialis muscle (BM). (A) Anteromedial view of the distal arm showing the MN and ulnar nerve (UN) before intramuscular penetration. The brachial artery (BA) is transected, and the musculocutaneous nerve (MCN) is identified in close relationship to the MN. The brachialis and biceps brachii muscles are evident (BM and BB). (B) Close-up view illustrating the MN traversing the BM. BB, UN, BT, BA, and the radial nerve (RN) are labeled for reference. RN is located lateral to BT. (C) Distal anterior view demonstrating the MN after emerging from the BM and reestablishing its superficial relationship with the BA. The BT, BB, UN, and RN are also identified. Orientation markers denote superior (S), inferior (I), medial (M), and lateral (L). Scale bars=1 cm.

Discussion

Abnormal courses of the MN in relation to the BM are rare. Bilecenoglu et al. (4) reported a cadaveric case in which the MN deviated from the BA and pierced the BM, while Loh et al. (2) and George and Nayak (5) described variants in which both the MN and BA traversed the BM within a common fascial sheath. Paraskevas et al. (1) documented an accessory MN branch piercing the BM and contributing to its innervation. In contrast, Barfi et al. (6) reported a case in which the MN passed deep into the BM. Additionally, Kumar et al. (3) described MN compression within an abnormal musculofascial tunnel formed by fibers of the BM and the medial intermuscular septum.

A distinguishing feature of the present case is the complete absence of MN innervation to the BM. Despite careful macroscopic examination, no motor or accessory branches were identified. This differentiates the present variation from previously described nerve-piercing configurations, in which intramuscular passage is frequently associated with supplementary muscular innervation (1, 4). The absence of a functional connection suggests a purely topographical deviation rather than a branching abnormality, a distinction that is clinically relevant because surgical decompression of the MN in this configuration would be unlikely to compromise BM function.

A developmental perspective may help explain the MN's atypical intramuscular course. During early upper-limb development (4th–6th gestational weeks), muscle primordia initially form as a premuscular mass and later differentiate through selective fusion and regression. Incomplete regression or atypical fusion of these primordia may result in persistent or aberrant muscle fascicles within the BM, potentially creating an abnormal intramuscular pathway. As peripheral nerves subsequently grow into the limb, their trajectories are influenced by surrounding developing muscles and connective tissue planes (7). Accordingly, an atypical brachialis fascicle could mechanically redirect the MN, explaining its deviation from the BA and intramuscular passage without associated

motor innervation. In addition, developmental variations of the MN may reflect altered brachial plexus formation due to abnormal neuronal growth cone guidance and rearrangement of nerve fibers, influenced by adjacent developing muscles and vascular structures (8). Together, these mechanisms support a topographical developmental variation rather than a true functional branching abnormality.

Proximal MN irritation or compression at the arm level may produce symptoms that can resemble pronator teres syndrome, including forearm discomfort, muscle stiffness, clumsiness, and reduced grip strength, which may develop gradually or following repetitive activity or muscle strain (3, 9). However, no clinical correlation can be inferred from the present cadaveric findings. Prolonged nerve compression, when present, may lead to intraneural edema and progressive nerve dysfunction (10).

Entrapment neuropathies are generally attributed to chronic mechanical factors that may result in nerve deformation and impaired intraneural microcirculation. Although such mechanisms are most commonly described in association with musculofascial tunnels, the present case demonstrates an unusual configuration in which the MN courses directly through the BM. The surrounding muscle fibers closely encircled the nerve along its intramuscular segment, indicating a restricted anatomical corridor. Because cadaveric observations cannot replicate in vivo biomechanical conditions, it can only be suggested that contraction of the BM during elbow flexion might further reduce the available space around the nerve, potentially increasing intraneural pressure. This configuration may therefore represent a potential anatomical substrate for MN irritation or compression, particularly during repetitive or forceful elbow movements (3, 9, 10).

Diagnosis of proximal MN entrapment in the presence of anatomical variation may be challenging. Physical examination findings can be nonspecific, and electrodiagnostic studies remain essential for confirming the level of nerve involvement (11). Imaging modalities, including magnetic resonance

imaging and high-frequency ultrasound, may help identify anatomical relationships and dynamic nerve behavior (12, 13). Management of proximal MN entrapment typically begins with conservative measures such as activity modification and anti-inflammatory treatment (14). In cases where a direct intramuscular anatomical constraint is suspected, a shorter trial of conservative management may be appropriate. If surgical intervention is required, decompression may be achieved by carefully releasing the surrounding muscle fibers, as described for proximal MN decompression (15).

Conclusions

This case documents a rare anatomical variation in which the MN traverses the BM without contributing to its innervation. Such a configuration may represent a potential anatomical substrate for proximal MN irritation or compression. Awareness of this variation is important for surgeons, anesthesiologists performing regional nerve blocks, and clinicians interpreting imaging studies or evaluating unexplained MN neuropathies. This report underscores the importance of detailed anatomical knowledge in accurate diagnosis and safe clinical practice.

What Is Already Known on This Topic:

The median nerve (MN) usually follows a predictable course in the arm, descending in close association with the brachial artery (BA) and lying adjacent to, but not innervating, the brachialis muscle (BM). Although rare, anatomical variations involving the relationship between the MN and the BM have been documented. These include accessory MN branches supplying the BM, cases in which both the MN and BA traverse the BM, passage of the nerve through musculofascial tunnels formed by the BM and the medial intermuscular septum, and courses in which the MN lies deep to the BM. Such variants may predispose to proximal median nerve irritation or compression and may complicate surgical approaches, regional anesthesia, and imaging interpretation. Only rare cadaveric reports have described penetration of the BM by the MN following separation from the BA.

What This Study Adds:

This study documents a rare cadaveric variation in which the MN traverses the BM without providing motor innervation. Unlike previously reported variants, the intramuscular course in this case is purely morphological, without evidence of functional muscular supply. Such a configuration may represent a potential anatomical substrate for proximal MN irritation or compression and may clinically resemble

pronator teres syndrome. In addition, this study provides insights into the anatomical basis of MN diagnosis and management. Awareness of this variant may improve diagnostic accuracy and help guide surgical procedures in the anterior compartment of the arm.

Authors' Contributions: Conception and design: GP and CL; Acquisition, analysis, and interpretation of data: GP, CL and MP; Drafting the article: CL, GT and AM; Revising it critically for important intellectual content: GP, CL, GT and AM; Final approval of the version to be published: GP, CL, GT, AM and MP.

Conflict of Interest: The authors declare that they have no conflict of interest.

Ethical Considerations: According to institutional guidelines, formal ethics committee approval was not required for this cadaveric study. All specimens were obtained through an accredited anatomical donation program, with informed consent provided in accordance with national and institutional ethical standards. Institutional approval was obtained for this cadaveric study. The corresponding ethical approval reference number is available upon request.

References

1. Paraskevas G, Anastasopoulos N, Nitsa Z, Kitsoulis P, Spyridakis I. Accessory branch of median nerve supplying the brachialis muscle: a case report and clinical significance. *J Clin Diagn Res.* 2014;8(12):AD01-2. doi: 10.7860/JCDR/2014/10128.5283. Epub 2014 Dec 5.
2. Loh HK, Singh S, Suri RK. Unusual Branching Pattern of the Lateral Cord of the Brachial Plexus Associated with Neurovascular Compression: Case report. *Sultan Qaboos Univ Med J.* 2017;17(1):e112-5. doi: 10.18295/squmj.2016.17.01.021. Epub 2017 Mar 30.
3. Kumar N, Padur AA, Prabhu G, Shanthakumar SR, Bhaskar R. Rare case of median nerve and brachial artery entrapment by an abnormal musculo-fascial tunnel in the arm: possible cause of neurovascular compression syndrome. *Anat Cell Biol.* 2019;52(1):84-6. doi: 10.5115/acb.2019.52.1.84. Epub 2019 Mar 29.
4. Bilecenoglu B, Uz A, Karalezli N. Possible anatomic structures causing entrapment neuropathies of the median nerve: an anatomic study. *Acta Orthop Belg.* 2005;71(2):169-76.
5. George BM, Nayak SB. Median nerve and brachial artery entrapment in the abnormal brachialis muscle – a case report. *Neuroanatomy.* 2008;7:41-2.
6. Barfi E, Hassanvand A, Rezaiean J, Boroujeni MB, Gholami M. A rare variation of the human median nerve direction. *Jentashapir Journal of Health Research.* 2016;7(2):e33877. doi: 10.17795/jjhr-33877.

7. Moore KL, Persaud TVN, Torchia MG. *The Developing Human: Clinically Oriented Embryology*. 11th ed. Philadelphia: Elsevier; 2020.
8. Ndahimana P, Habumuremyi S, Niyibigira C, Archibong VB, Okesina A, Twagirumugabe T, et al. Variations in the terminal branches of the brachial plexus in humans. A cadaveric study. *Morphologie*. 2026;110(368):101102. doi:10.1016/j.morpho.2025.101102. Epub ahead of print.
9. Löppönen P, Hulkkonen S, Ryhänen J. Proximal Median Nerve Compression in the Differential Diagnosis of Carpal Tunnel Syndrome. *J Clin Med*. 2022;11(14):3988. doi: 10.3390/jcm11143988.
10. Paraskevas G, Natsis K, Ioannidis O, Papaziogas B, Kitsoulis P, Spanidou S. Accessory muscles in the lower part of the anterior compartment of the arm that may entrap neurovascular elements. *Clin Anat*. 2008;21(3):246-51. doi: 10.1002/ca.20608.
11. Stretanski MF, Dydyk AM, Cascella M. Median Nerve Injury. [Updated 2025 Jul 7]. In: StatPearls [Internet]. Treasure Island (FL): StatPearls Publishing; 2026 Jan-. Available from: <https://www.ncbi.nlm.nih.gov/books/NBK553109/>.
12. Klauser AS, Buzzegoli T, Taljanovic MS, Strobl S, Rauch S, Teh J, et al. Nerve Entrapment Syndromes at the Wrist and Elbow by Sonography. *Semin Musculoskelet Radiol*. 2018;22(3):344-53. doi: 10.1055/s-0038-1641577. Epub 2018 May 23.
13. Meyer P, Lintingre PF, Pesquer L, Poussange N, Silvestre A, Dallaudière B. The Median Nerve at the Carpal Tunnel ... and Elsewhere. *J Belg Soc Radiol*. 2018;102(1):17. doi: 10.5334/jbsr.1354.
14. Delzell PB, Patel M. Ultrasound-Guided Perineural Injection for Pronator Syndrome Caused by Median Nerve Entrapment. *J Ultrasound Med*. 2020;39(5):1023-9. doi: 10.1002/jum.15166. Epub 2019 Nov 9.
15. Hagert E. Clinical diagnosis and wide-awake surgical treatment of proximal median nerve entrapment at the elbow: a prospective study. *Hand (N Y)*. 2013;8(1):41-6. doi: 10.1007/s11552-012-9483-4.